Parasitology review

MEDICAL TECHNOLOGY LICENSURE EXAM REVIEW – **CLINICAL MICROBIOLOGY**

PARASITOLOGY

Lecturer: Isaac Edron J. Orig, RMT
Notes by: Xiao - The Conqueror of Demons, The Vigilant Yaksha, & Alatus, the Golden-Winged King

CHARACTERISTICS OF VIRUSES

COMMON NAMES OF PARASITES	
SCIENTIFIC NAME	**COMMON NAME/INFECTION**
INTESTINAL NEMATODES	
Ascaris lumbricoides	- Giant intestinal round worm - Largest intestinal nematode - Gangrene (obstruction of bowel/blood vessels), wormball (obstruction of intestines)
HOOKWORMS	
Ancylostoma duodenale	- Old World Hookworm
Necator americanus	- New World Hookworm
Ancylostoma caninum *Ancylostoma braziliense*	- Cutaneous larva migrans (creeping eruption)
Ancylostoma ceylanicum	- Golden hamster hookworm - Small hookworm
Toxocara canis and cati	- Animal ascarids - Visceral larva migrans; larva invades the internal organs - Toxocariasis - *Toxocara canis*: dog ascarid - *Toxocara cati*: cat ascarid
Enterobius vermicularis	- Pin worm - Seat worm - Sofa worm - Inhaled worm - Day care/ social/ community/ kindergarten worm - Familial worm - Pruritus ani
Trichuris trichiura	- Whipworm - Ova: Lemon/ football/ barrel/ Japanese lantern
Strongyloides stercoralis	- Threadworm - Cochin-china diarrhea/ Vietnam diarrhea
Capillaria philippinensis	- Mystery/ Pudoc/ Peanut/ Bagsit worm
Anisakis	- Fish and marine mammal worm - Herring's worm
TISSUE NEMATODES	
Angiostrongylus cantonensis Now: *Parastrongylus cantonensis*	- Rat/Rodent lungworm - Causes eosinophilic meningoencephalitis
Trichinella spiralis	- Trichina worm - Muscle worm - Diagnostic procedure: Muscle biopsy
Dracunculus medinensis	- Fiery serpent worm - Longest nematode that can affect humans
FILARIAE (BLOOD/TISSUE NEMATODES)	
Wuchereria bancrofti	- Bancroftian elephantiasis - Affects the lower extremities
Brugia malayi	- Malayan elephantiasis - Affects upper extremities
Loa loa	- African eye worm
Onchocerca volvulus	- Blinding worm - River blindness
Dirofilaria immitis	- Dog tissue nematode
CILIATE	
Balantidium coli	- Only pathogenic ciliate - Pork ciliate - Largest intestinal protozoan
FLAGELLATES	
Giardia lamblia A.k.a. *Giardia intestinalis*	- Gay bowel syndrome (fecal-oral route) - Steatorrhea, malabsorption (Leningrad's curse) - Trophozoite: old man with glasses, smiling face, tennis racket without handle
Chilomastix mesnili	- Shepherd's crook shape - Cyst: lemon/nipple shaped
Trichomonas vaginalis	- Vaginal flagellate - Pingpong disease (transmitted during intercourse), strawberry cervix - Male: asymptomatic
Trichomonas tenax	- Oral flagellates
HEMOFLAGELLATES	
Trypanosoma cruzi	- American trypanosomiasis - Chagas disease – Chagoma, Romana's sign (swelling of the eyelids)
Trypanosoma brucei gambiense	- West African Sleeping Sickness - Winterbottom sign (swelling of the posterior cervical lymph node) - More pathogenic than *rhodesiense*
Trypanosoma brucei rhodesiense	- East African Sleeping Sickness
Leishmania donovani	- Visceral Leishmaniasis - Dumdum fever, Kalaazar disease
Leishmania tropica	- Old world cutaneous leishmaniasis - Dehli boils, pian boils, oriental sore, Uta sore
Leishmania mexicana	- New world cutaneous leishmaniasis - Chiclero ulcero of the external ear
Leishmania braziliensis	- Mucocutaneous leishmaniasis - Espundia
SPOROZOA (MALARIAL PARASITES)	
Plasmodium vivax	- Benign tertian malaria (48 hours)
Plasmodium ovale	- Benign tertian malaria (48 hours)
Plasmodium falciparum	- Malignant tertian malaria - Blackwater malaria (due to excessive hemolysis) - Most pathogenic Plasmodium
Plasmodium malariae	- Benign quartan malaria (72 hours) - Least pathogenic
TREMATODES	
LIVER FLUKES	
Clonorchis sinensis	- Oriental/Chinese Liver Fluke
Opisthorchis felineus	- Cat Liver Fluke
Fasciola hepatica	- Sheep Liver Fluke - Temperate Liver Fluke (at colder climate)
Fasciola gigantica	- Giant Liver Fluke - Tropical Liver Fluke (at warm climate)
INTESTINAL FLUKES	
Fasciolopsis buski	- Giant Intestinal Fluke
Echinostoma ilocanum	- Garrison's fluke
Heterophyes heterophyes	- Von Siebold's Fluke - Smallest and most dangerous fluke
BLOOD FLUKES (*Schistosoma spp.*)	
Schistosoma japonicum	- Oriental blood fluke
Schistosoma mansoni	- Manson's blood fluke
Schistosoma haematobium	- Vesicle blood fluke
LUNG FLUKE	
Paragonimus westermani	- Oriental lung fluke - IH: *Sundathelphusa philippina* (freshwater mountain crab) - Pulmonary TB-like infection
CESTODES	
Diphyllobothrium latum	- Broad fish tapeworm - Vitamin B12 deficiency anemia
Taenia solium	- Pork tapeworm - Cysticercosis
Taenia saginata	- Beef tapeworm
Hymenolepis nana	- Dwarf tapeworm - Smallest tapeworm
Hymenolepis diminuta	- Rat tapeworm
Echinococcus granulosus	- Hydatid cyst tapeworm
Echinococcus multilocularis	- Fox tapeworm
Dipylidium caninum	- Dog tapeworm - Double pore tapeworm/pregnant tapeworm - 2 genital pores

INFECTIVE STAGES	
Cyst	- Protozoans (amoebae) - *Entamoeba histolytica*
Trophozoite	- *Trichomonas vaginalis*
Sporozoites	- *Plasmodium spp.*
Trypomastigote	- *Trypanosoma spp.*
Promastigote	- *Leishmania spp.*
Embryonated egg	"HATE" - *Hymenolepis nana* - *Ascaris lumbricoides* - *Trichuris trichiura* - *Enterobius vermicularis*
3rd stage larva	- *Wuchereria bancrofti* - *Brugia malayi* - *Angiostrongylus cantonensis* - *Loa loa* - *Onchocerca volvulus* - *Mansonela*
Filariform larva	- Hookworm - *Strongyloides stercoralis*
Cercaria	- *Schistosoma spp.*
Metacercaria	- *Fasciola hepatica* - *Fasciolopsis buski* - *Clonorchis sinensis* - *Opisthorchis felineus* - *Paragonimus westermani* - *Echinostoma ilocanum* - *Heterophyids*
Cysticercus cellulosae	- *Taenia solium*
Cysticercus bovis	- *Taenia saginata*
Plerocercoid larva	- *Diphyllobothrium latum*
Hydatid cyst	- *Echinococcus granulosus*
Cysticercoid larva	- *Hymenolepis diminuta* - *Dipylidium caninum*

BASIC PRINCIPLES IN PARASITOLOGY

Parasitology	- The area of biology concerned with the phenomenon of dependence of one living organism on another.
Medical Parasitology	- Concerned primarily with parasites that affect humans and their medical significance, as well as their importance in human communities.
MEDICAL RELATIONSHIPS	
Symbiosis	- Living together of unlike organisms, may involve protection or other advantages to one or both organisms
Commensalism	- 2 species living together and one species benefits from the relationship without harming or benefitting the other - Ex. *Entamoeba coli* in the human intestinal lumen
Mutualism	- 2 organisms mutually benefit from each other - Ex. *Mycorrhizae* and tree
Parasitism	- 1 organism, the parasite, lives in or on another depending on the host for its survival
CLASSIFICATION OF PARASITES	
ACCORDING TO HABITAT	
Endoparasite	- Parasite living inside the body of a host - Most of the medically significant parasites are endoparasites - Infection: presence of endoparasites
Ectoparasite	- Parasite living outside the body of a host - Infestation: presence of ectoparasites
Erratic	- Found in an organ which is usually not its habitat - Ex. *Ascaris lumbricoides* which usually infects the small intestine but can also invade the heart
ACCORDING TO MODE OF DEVELOPMENT	
Obligate/Obligative parasites	- Needs a host at some stage of their life cycle to complete their development
Facultative parasites	- May exist in a free-living state or may become parasitic when the need arises - Ex. *Strongyloides stercoralis*
Accidental/Incidental parasites	- Establishes itself in a host where it does not ordinarily live - Ex. *Balantidium coli* (parasite of the pigs; but can infect humans)
Permanent parasites	- Remains on or in the body of the host for its entire life - Ex. *Trichinella spiralis*
Temporary parasites	- Lives on the host for only a short period of time
Spurious/Coprozoic parasites	- Free-living organism that passes through the digestive tract without infecting the host - Ex. *C. philippinensis* in the liver of animals
HOSTS	
Definitive/Final host	- Where the parasite attains sexual maturity - Ex. Humans in the life cycle of *C. philippinensis*
Intermediate host	- Harbors the asexual or larval stage of the parasite - Ex. Fish/copepods in the life cycle of *C. philippinensis*
Paratenic hosts	- One in which the parasite does not develop further to later stages but remains alive and is able to infect another host
Reservoir	- Allow the parasite's life cycle to continue and become additional sources of human infections - Ex. rats, rodents
Accidental host	- Host in which a parasite is not usually found
VECTORS	
Biological vector	- Transmits the parasite only after the parasite has completed its development within the host
Mechanical/Phoretic vector	- Only transports the parasite
EXPOSURE AND INFECTION	
Exposure	- Process of inoculating an infective agent
Infection	- Establishment of the infective agent in the host
Clinical incubation	- Period between the infection and evidence of symptoms
Biological incubation	- Period between the infection or acquisition of the parasite and evidence or demonstration of infection
Autoinfection	- Refers to when an infected individual becomes his own direct source of infection
MODES OF TRANSMISSION	
Ingestions/Fecal-Oral	- *T. solium, T. saginata, D. latum*
Skin penetration	- Hookworms, *S. stercoralis, Schistosoma spp.*
Vector borne infections	- Malarial parasites, Filarial parasites, *Leishmania spp., Trypanosoma spp., Babesia spp.*
Congenital	- *Toxoplasma gondii*
Transmammary	- Parasites that can be transmitted through a mother's milk - *Ancylostoma* - *Strongyloides*
Inhalation	- *Enterobius vermicularis*
Sexual contact	- *Trichomonas vaginalis*

QUESTION AND ANSWER PORTION

1. Two species live together and one species benefits from the relationship without harming or benefitting the other
   a. Symbiosis
   b. Commensalism
   c. Mutualism
   d. Parasitism
2. One organism, the parasite, lives in or on another, depending on the host for its survival
   a. Symbiosis
   b. Commensalism
   c. Mutualism
   d. Parasitism
3. What is the mode of transmission of *S. stercoralis*?
   a. Ingestion
   b. Skin penetration
   c. Congenital
   d. Sexual contact
4. This is a vector that only transports the parasite
   a. Biological
   b. Phoretic
5. This is a free-living organism that passes through the digestive tract without infecting the host
   a. Spurious
   b. Permanent
   c. Obligate
   d. Incidental

CLASSIFICATION OF PARASITES

PROTOZOANS Single-celled eukaryotes		
A. Amoeba B. Ciliates C. Flagellates D. Sporozoans and Coccidians E. Microspora		
METAZOANS Multiple-celled eukaryotes		
NEMATODES Roundworms	**CESTODES** Flatworms	**TREMATODES** Flukes/Leaf-shaped
A. Intestinal B. Tissue and Blood	A. Intestinal B. Tissue	A. Intestinal (*F. buski, E. ilocanum*) B. Liver (*C. sinensis, F. hepatica*) C. Blood (*Schistosoma*) D. Lung (*P. westermani*)

PROTOZOA

- Unicellular
- Provided with a nucleus or nuclei, cytoplasm, membrane, and organelles
- Divides through binary fission
- Contains vacuoles for storage and transport
- Locomotory apparatuses:
  - Pseudopodia: found among amoeba; blunt cytoplasmic extensions
  - Cilia: small finger-like extensions from the cytoplasm
  - Flagella: long thread-like extensions from the cytoplasm
- Cysts
  - Infective/non-feeding stage, relatively resistant to environmental changes, nonmotile, found in formed stools
- Trophozoite
  - Vegetative stage, less resistant, motile, found in fluid or watery sample, destroyed by iodine
- Encystation
  - Trophozoite to cyst
  - Happens in the large intestine
- Excystation
  - Cyst to trophozoite
  - Happens in the small intestine (rich in nutrients)
- Kingdom: Protista
- Phyla (according to locomotory apparatus):
  - Sarcomastigophora
    - Subphylum Mastigophora: Flagellates
    - Subphylum Sarcodina: Amoeba
  - Apicomplexa (complex locomotory apparatuses)
    - *Plasmodium, Toxoplasma, Babesia, Cryptosporidium, Cyclospora*
  - Ciliophora
    - *B. coli*
  - Microspora (fungi)
    - *Encephalitozoon spp.* & *Microsporea*
- Protoplasm: unit that performs the vital function
- Contracting vacuole: regulation and maintenance of osmotic pressure

AMOEBA (Class Rhizopoda)

- With cystic stage, except *E. gingivalis*
- Inhabits the large intestine, except *E. gingivalis* (oral cavity, gums)
- Commensals (non-pathogenic), except *E. histolytica* (pathogenic)
- Amoebiasis: infection of *E. histolytica*

Difference between amoebae

ENTAMOEBA	ENDOLIMAX/IODAMOEBA
- True amoeba - With peripheral chromatin - With chromatoidal bars	- Other/minor amoeba - No peripheral chromatin - No chromatoidal bars

Entamoeba histolytica

- Most invasive of the parasites (invade a lot of organs)
- Humans are the only hosts
- 2 stages
  - Cyst
    - Infective stage
    - Quadrinucleated (has 4 nuclei)
    - With rod or cigar-shaped chromatoidal bars
  - Trophozoite
    - Invasive
    - Motile (characteristic progressive and directional)
    - Possess pseudopodia (finger-like shaped extensions)
    - With ingested RBCs (hematophagous)
- Modes of transmission
  - Cysts are ingested from fecally-contaminated material
  - Venereal transmission (fecal-oral)
  - Contaminated enema equipment (enema: injection of fluid into the lower bowel through the rectum)
- No morphological difference with
  - *E. dispar, E. moshkovskii, E. histolytica*
  - Differentiated through PCR and serological tests
- Clinical manifestations
  - Amoebic colitis – intestinal/non dysenteric colitis/ no diarrhea
  - *E. histolytica* has lectin that can attach to the N-acetylgalactosamine sugars on the surface of the epithelial cells in the intestine
  - Extraintestinal
    - Liver – most commonly affected extraintestinal organ; manifests as acute nonsuppurative liver disease (right lobe more common)
    - Lungs – lung atelectasis (collapse of alveoli in the lungs)
  - Flask-shaped ulcer
  - "Buffalo skin" or "Dyak hair" ulcers
- Diagnosis
  - Minimum of 3 stool specimens
  - Unidirectional, progressive – trophozoite motility
    - Observed using Direct fecal smear
    - Stain's used:
      - Quensel's iodine (best)
      - Methylene blue
      - Lugol's iodine
      - Di Antonis
    - Concentration technique: ex. FECT
    - Colonoscopy and Sigmoidoscopy
    - ELISA testing
    - Culture – best: Locke's Egg Serum medium
- Treatment
  - Metronidazole: treatment of choice for invasive Amoebiasis
  - Diloxanide furoate: drug of choice for asymptomatic cyst passers

Differences between Bacillary and Amoebic Dysentery

BACILLARY DYSENTERY	AMOEBIC DYSENTERY
- Acute onset - Vomiting common - Odorless stool - Without Charcot-Leyden crystals	- Gradual onset - No vomiting - Fishy odor stool - With Charcot-Leyden crystals (inclusion bodies left by eosinophils)

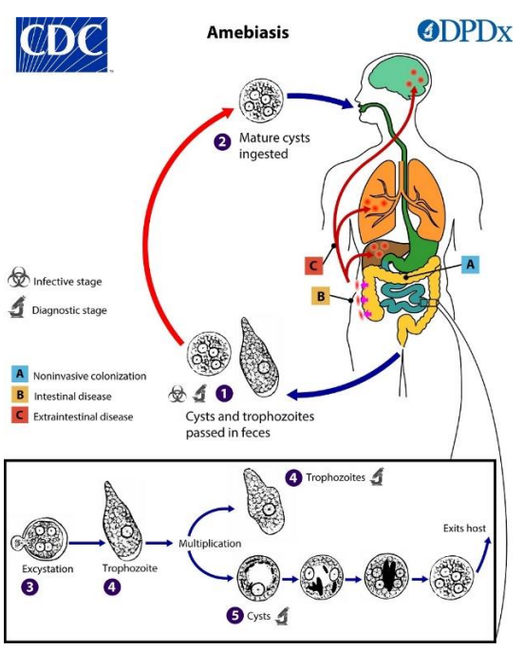

Entamoeba histolytica	*Entamoeba coli*
Trophozoite	
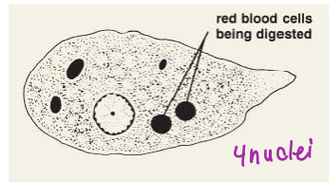	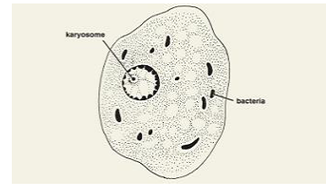
Cysts	
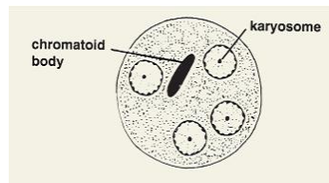	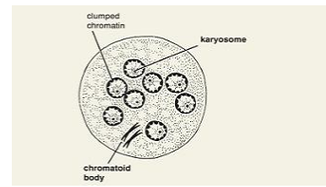

Entamoeba coli

Stage		*E. histolytica*	*E. coli*
Cyst	Number of nuclei	Quadrinucleated (4) Mature <4	Octanucleated (8) Mature >4
	Chromatoidal bars	Sausage shaped Rounded ends Cigar shaped	Witch broomstick Splintered or needle-like ends
Trophozoite	Movement	Progressive, unidirectional	Sluggish, nonprogressive
	Shape of pseudopodia	Fingerlike	Blunt
	Ingest RBCs	Yes	No
	Nucleus (karyosome)	Central	Eccentric
	Cytoplasm	Clear	Dirty

Entamoeba hartmanni

- Small-race *E. histolytica*
- Only clear cut distinction is size (Troph: 12 um, cyst: 10 um)
- No RBCs in the cytoplasm

Entamoeba polecki

- Found in the intestines of pigs and monkeys
- Humans are accidental hosts
- "Sluggish" motility of trophozoites
- Cyst with single nucleus
- With mass inclusion

Entamoeba gingivalis

- Kissing amoeba
- Associated with gum infections
- Acquired through sharing utensils and kissing
- Only amoeba not found in the intestine
- Trophozoite
  - Karyosome: small and centrally-located
  - Pseudopodia: similar to *E. histolytica* but does not show progressive motility
- No cyst stage

Endolimax nana

- Cross-eyed cyst
- Large-irregular blot-like karyosome
- No peripheral chromatin
- Smallest amoeba (size = RBC)

Iodamoeba butschlii

- Trophozoite with achromatic granules (described as "bouquet of flowers")
- Cyst with glycogen granules (stained with iodine)

Organism	Trophozoite	Precyst	Cyst
E. histolytica *E. dispar* *E. moshkovskii*	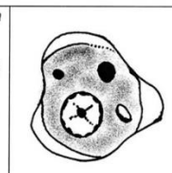		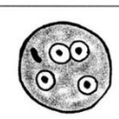
E. coli	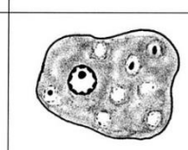	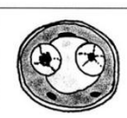	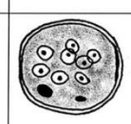
E. hartmanni	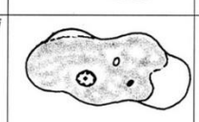	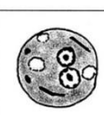	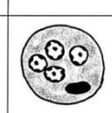
I. bütschlii	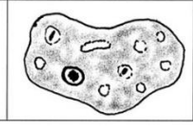		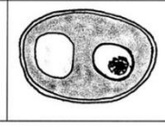

FREE-LIVING PATHOGENIC AMOEBAE (OPPORTUNISTIC AMOEBAE)

- Inhabits the CNS
- Does not indicate fecal contamination

Naegleria fowleri

- Causative agent Primary Amoebic Meningitis/Meningoencephalitis (PAM)
- Acquired when swimming during hot weather in brackish/freshwater (nasal passage; enter the CNS via the olfactory nerves)
- 2 morphologic forms
  - Amoeboid: blunt pseudopodia, trophozoite form, found in CSF and tissues
  - Flagellate: pear-shaped with 2 anterior flagella, swimming form, found in CSF
- Treatment
  - Amphotericin B
  - Clotrimazole
  - Azithromycin

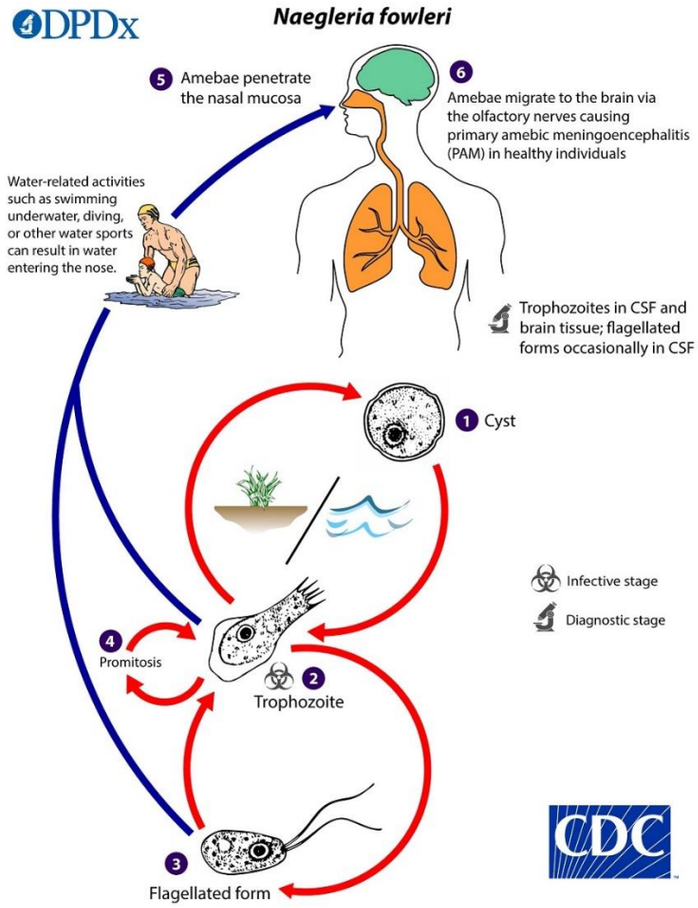

Acanthamoeba spp.

- *Acanthamoeba polyphaga* is most common
- Causative agent of Granulomatous Amoebic Encephalitis (GAE)
- Contaminated contact lens solution presents with keratitis
- 2 forms
  - Trophozoite: spiny filaments for locomotion
  - Cyst: double-walled wrinkled cyst
- Clinical manifestations
  - Ataxia and hemiparesis
  - Amoebic keratitis
  - Corneal ulcer, sclerosis, blindness
- Diagnosis
  - PYGC (Potato Yeast Glucose Culture) Medium
- Treatment
  - SXT (Sulfamethoxazole-Trimethoprim)

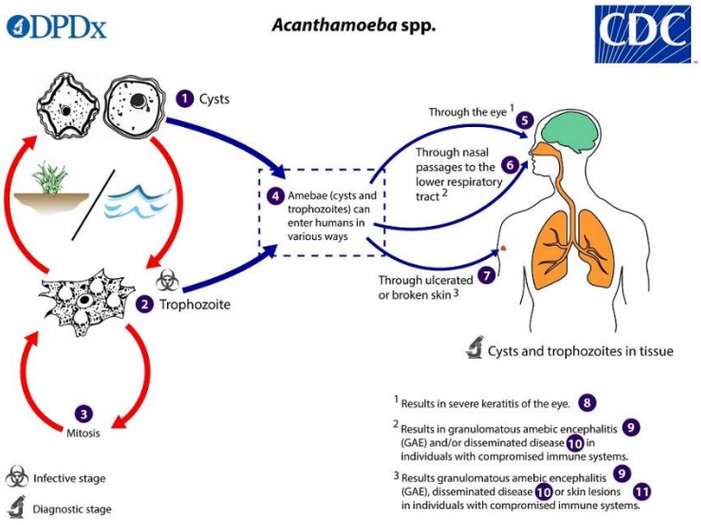

CILIATE

Balantidium coli

- Largest protozoan parasite affecting humans
- Only significant ciliate (hyaluronidase)
- Reservoir host: pigs
- Mode of transmission: ingestion of cysts (swine feces)
- Characteristic motility: thrown ball, rolling ball
- 2 forms
  - Trophozoite
    - Macronucleus: kidney-shaped, vegetative
    - Micronucleus: dot-like, reproductive
  - Cyst
    - Non-motile
    - Double-wall enclosing cilia
- Clinical Manifestations
  - Balantidial dysentery
  - Wine glass ulceration (round base and wide neck)
  - Asymptomatic carriers
- Treatment
  - Tetracycline
  - Metronidazole
  - Iodoquinol

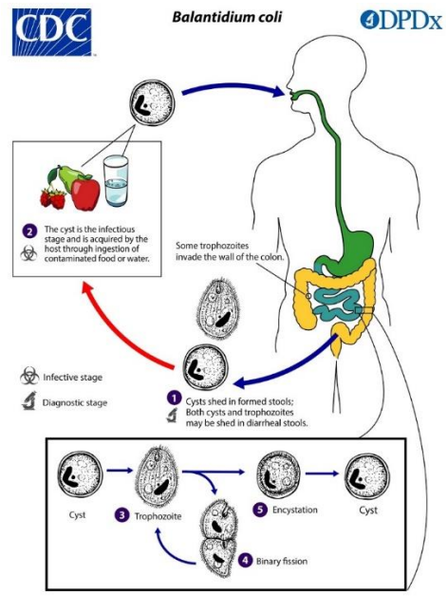

ATRIAL/INTESTINAL FLAGELLATES

Giardia duodenalis

- A.k.a. *Giardia intestinalis* and *Giardia lamblia*
- Associated with gay bowel syndrome
- Only protozoan intestinal flagellate (live in the small intestine of humans; duodenum)
- Only protozoa with a sucking disk for attachment
- 2 forms
  - Trophozoite
    - Pear/teardrop shaped
    - 4 pairs of flagella and axostyle
    - Divide by longitudinal binary fission
    - Old man with eyeglasses/Smiling face appearance
    - Movement: jerky, falling leaf, kite-like

  - Cyst
    - Flagella retracted into axonemes

- Clinical Manifestations
  - Attachment at pH 3-8
  - Steatorrhea: passage of greasy, frothy stool that floats on toilet water (>6g/72 hours)
  - Traveler's diarrhea
  - Malabsorption: Leningrad's curse
  - Intestinal inflammation
- Diagnostic tests
  - DFS
  - Zinc Sulfate Flotation
  - Duodenal aspiration
  - Enterotest – trophozoite of *G. lamblia*

Chilomastix mesnili

- Commensal
- 2 forms
  - Trophozoite
    - Diagnostic stage
    - Pear shaped (shepherd's crook)
    - Spiral boring, forward movement
    - Spiral groove across body
  - Cyst
    - Infective stage
    - Lemon/nipple-shaped because of anterior knob-like prominence
- Diagnosis
  - Best stain: Iron hematoxylin
  - Found in the cecal region of the colon

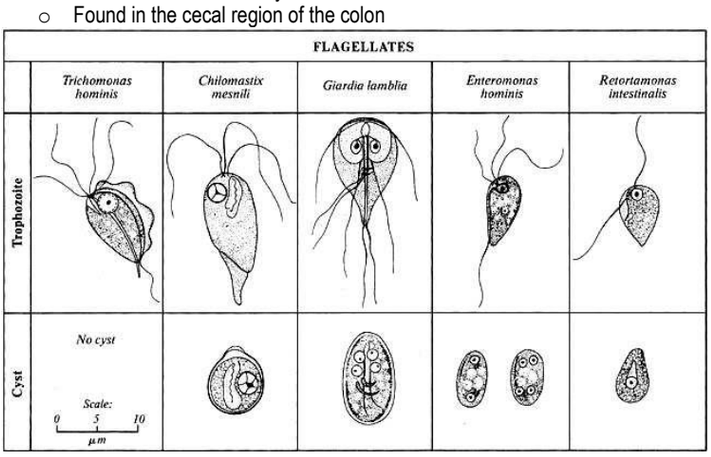

Dientamoeba fragilis

- Now a flagellate (no longer an amoeba)
- With only a trophozoite stage known
- Rosette shaped nuclei
- Binucleated trophozoite
- No cyst stage
- Closely related to *Trichomonas spp.*
- Obtained via transmission of *E. vermicularis* and *A. lumbricoides* eggs
- Clinical Manifestations
  - Resembles IBS (Irritable Bowel Syndrome)
  - Colicky abdominal pain

TRICHOMONADS

- Trophozoite stage only
- Pear-shaped
- Jerky motility
- Flagella: aids in locomotion
- Undulating membrane: thickening of membrane

Trichomonas vaginalis

- Only pathogenic Trichomonas
- Reproduce by longitudinal binary fission
- Pingpong disease
- Females
  - Vaginal discharge (irritation and itchiness)
  - Punctate hemorrhages of cervix; Strawberry cervix
  - Endometritis
- Males
  - Mostly asymptomatic
  - Prostatitis: most common complication
- Diagnosis
  - Wet preparation: quickest and most inexpensive way; uses NSS
  - Culture: Gold standard (Diamond's modified medium)
  - Pap smear
- Treatment
  - Metronidazole – drug of choice when pregnant
  - Tinidazole

DIFFERENCE BETWEEN TRICHOMONADS

	T. vaginalis	*T. tenax*	*T. hominis*
Habitat	Genitalia	Oral cavity	Intestines
Size	Largest	Smallest	Intermediate
Nucleus	Ovoid	Round	Ovoid
Inclusion bodies	Siderophil granules	None	None
Specimen	Urine Females: vaginal swab, vaginal discharge, urethral discharge Males: prostatic secretions	Oral scrapings	Stool
Undulating membrane	½ of the costa	2/3 of the costa	As long as the costa

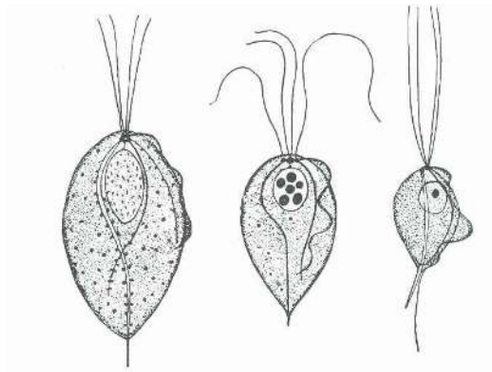

Fig. 19-12. *Trichomonas vaginalis, Trichomonas tenax* y *Trichomonas hominis.* × 2.000. (Powell.)

QUESTION AND ANSWER PORTION

1. This is the gold standard for *T. vaginalis* diagnosis
   a. Culture
   b. Serology
   c. Wet mount
   d. Giemsa
2. This parasite presents with a characteristic "flask-shaped" ulceration
   a. *T. vaginalis*
   b. *C. mesnili*
   c. *B. coli*
   d. *E. histolytica*
3. This parasite is the causative agent for PAM
   a. *Acanthamoeba spp.*
   b. *N. fowleri*
   c. *D. fragilis*
   d. *E coli*
4. Which Trichomonad uses oral scrapings for diagnosis?
   a. *T. vaginalis*
   b. *T. tenax*
   c. *T. hominis*
   d. *T. trichiura*
5. What inclusions are found in *Entamoeba histolytica* trophozoites?
   a. Rounded chromatoidal bars
   b. Splintered chromatoidal bars
   c. RBCs
   d. Platelets
6. What is the largest intestinal protozoan?
   a. *B. coli*
   b. *E. coli*
   c. *E. histolytica*
   d. *D. fragilis*
7. This is the reproductive nucleus of *Balantidium coli*?
   a. Macronucleus
   b. Micronucleus
8. The trophozoite of this flagellate is characterized as "Shepherd's crook" in appearance
   a. *G. duodenalis*
   b. *C. mesnili*
   c. *T. vaginalis*
   d. *T. tenax*
9. Protozoans with pseudopodia are classified under
   a. Sarcodina
   b. Mastigophora
10. A formed stool sample is passed to the lab. Which of the following will you most likely see during microscopy?
    a. *E. histolytica trophs*
    b. *E. histolytica cysts*
    c. *T. vaginalis trophs*
    d. *T. vaginalis cysts*

BLOOD AND TISSUE FLAGELLATES

- Hemoflagellates include Leishmania and Trypanosoma
- May infect the blood, lymph nodes, muscles, and the reticuloendothelial system
- Stages of development
  - Amastigote or Leishmaniad: ovoid, devoid of flagellum
  - Promastigote or Leptomonad: elongate, kinetoplast anterior to the nucleus, flagellum at the anterior end of the body
  - Epimastigote or Crithidial: elongated with juxtanuclear kinetoplast, short flagellum
  - Trypomastigote or Trypanosomad: postnuclear kinetoplast, long flagellum

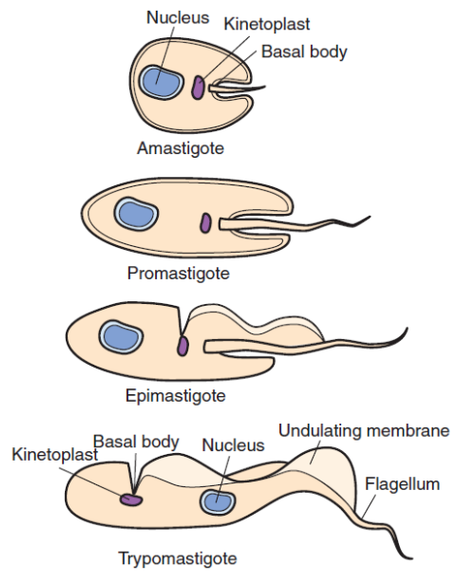

• **Figure 48-7** Characteristic stages of species of *Leishmania* and *Trypanosoma* in human and insect hosts.

TRYPANOSOMES

- Stercorarian trypanosomes: *T. cruzi*
  - "Sterco" = feces; the vector defecates on the skin where it bit the host
- Salivarian trypanosomes: *T. brucei gambiense, T. brucei rhodesiense*
  - Transmission through the saliva of the vector

1 ***Trypanosoma cruzi***
- Agent of Chagas disease, American Trypanosomiasis
- Characteristic C-shape
- Romanas sign: unilateral swelling of the eyelids/Chagoma
- Infective stage: Trypomastigote
- Diagnostic stage: Amastigote
- Habitat: RES, cardiac muscle, CNS
- Vectors
  - Reduuvid bugs, kissing bugs, assassin bugs, Triatomine bugs
  - *Triatoma rubrofasciata* – in the Philippines
- Diagnosis
  - Xenodiagnosis
  - Culture – Weinman's medium or Chang's medium
- Most common complication: Megacolon

2 ***Trypanosoma brucei gambiense***
3 ***Trypanosoma brucei rhodesiense***
- Agent of
  - East African Sleeping Sickness: *T. brucei rhodesiense*
  - West African Sleeping Sickness: *T. brucei gambiense*
- Vector: Tse tse fly (Glossina)
- Infective & Diagnostic stage: Trypanosomes
- Clinical manifestations
  - Winterbottom's sign: swelling of lymph nodes at the back of the neck/below the chin
  - *T. brucei gambiense* frequently infects the CNS
- Diagnosis
  - CATT: Cart Agglutination Test for Trypanosomiasis
  - Febrile stage: Blood and lymph nodes
  - Sleeping stage: CSF

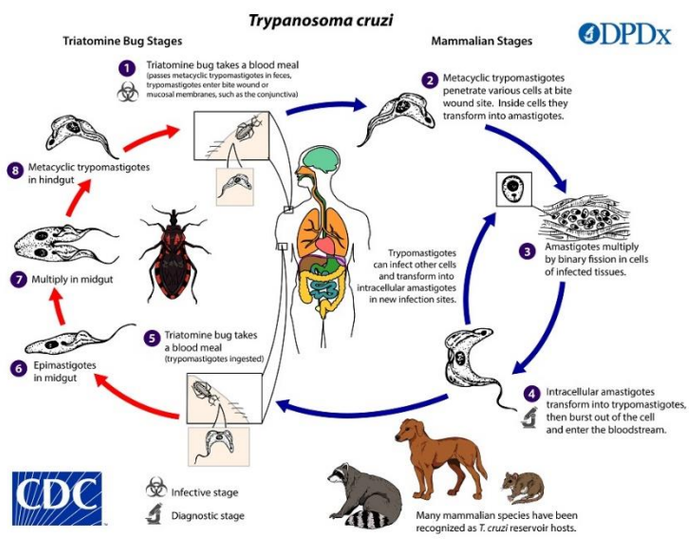

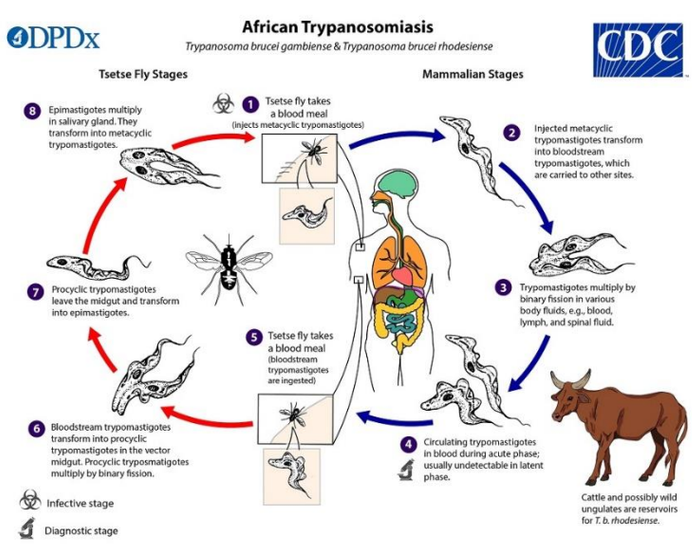

LEISHMANIA

1 ***Leishmania donovani***
- Agent of
  - Visceral Leishmaniasis
  - Dumdum fever
  - Kala-azar disease/black disease
- Vectors
  - Phlebotomus, Lutzomiya
- Pathogenesis
  - Splenomegaly and severe anemia (enlarged spleen: increased destruction of RBCs)
- Diagnosis
  - Culture using NNN (Nicole-Novy-McNeal)
  - Screening test: Formol Gel Test – 1mL serum + 1 drop formalin = (+) gel formation

2 ***Leishmania tropica***
- Agent of
  - Old World Cutaneous Leish
  - Delhi boils
  - Pian boils
  - Oriental sore
  - Uta sore
- Vector: Phlebotomus, Lutzomiya
- Clinical manifestations
  - Localized Cutaneous Infection (Macule – Papule)

3 ***Trypanosoma brucei rhodesiense***
- Agent of
  - Mucocutaneous Leishmaniasis
  - Espundia
  - Wheeping lesions
- Vector: Tse tse fly (Glossina)
- Infective & Diagnostic stage: Phlebotomus, Lutzomiya
- Pathogenesis
  - Wheeping lesions
- Diagnosis
  - Dr. Montenegro's test (Skin test)

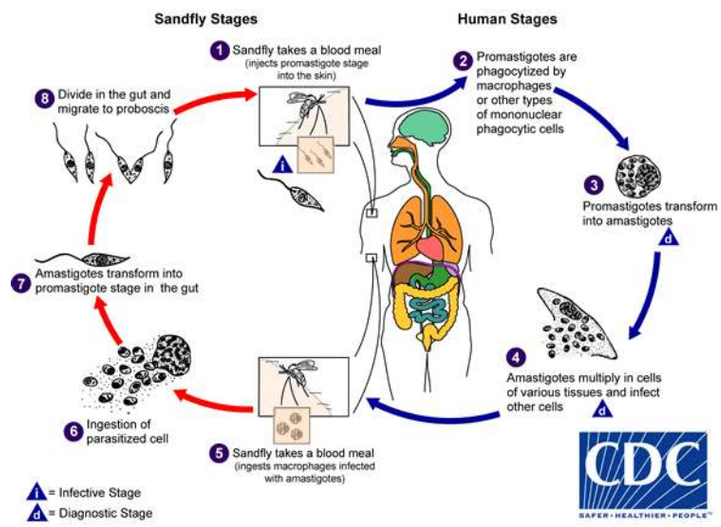

COCCIDIANS

- Largest group of Apicomplexan protozoans falling under class Conoidasida
- Among humans, are considered to be opportunistic in immunocompromised and immunodeficient individuals
- Infective stage: oocysts
- Sexual cycle or sporogony: produces oocysts
- Asexual cycle or schizogony: produces merozoites
- Gametogony: development of macro and microgametocytes

Cryptosporidium hominis

- Self-limiting diarrhea
- Oocysts containing 4 sporozoites (waterborne transmission)
- Diagnosis:
  - Sheathers sugar flotation (improves oocyst recovery/yield)
  - Stool examination
  - Kinyoun acid fast staining: oocysts appearing as red or pink donuts in a blue background

Cyclospora cayatenensis

- Thought to be a member of cyanobacteria due to showing photosynthesizing organelles and autofluorescing particles
- Originally called "Cyanobacterium-like body (CLB)"
- Cause D-xylose malabsorption
- Oocysts are autofluorescent and appear as blue or green circles

Cytoisospora belli

- Causative agent of Cytoisosporiasis
- May be asymptomatic or may present as self-limiting gastroenteritis
- Diagnosis:
  - Zinc flotation
  - Sheathers sugar
  - AFS

Toxoplasma gondii

- Common cause of congenital infections
- Encephalitis: most common manifestation
- Stillbirth and abortion may result when mothers acquire the infection during the 1st-2nd trimester of pregnancy
- Definitive host: Cat (Sporogony)
- Intermediate host: Human (Schizogony)
  - Bradyzoites: inactive form
  - Tachyzoites: active form
- Laboratory diagnosis:
  - Methylene blue
  - Sabin-Feldman dye (most common)

Sarcocystis spp.

- Zoite: simplest form (banana-shaped)
- Man is the definitive host
- Eosinophilia, elevated ESR, elevated CK levels
- Definitive diagnosis: Sarcocysts in tissue specimen
- Confirmatory stain: PAS/Acid fast

PLASMODIUM SPP.

- Malaria (bad air) – leading parasitic disease that causes mortality worldwide
- Clinical manifestations (malarial attack or paroxysm)
  - Cold paroxysm (chills, shivering, rigidity of muscles)
  - Hot paroxysm (greater than 100°F fever)
  - Diaphoresis (excessive sweating)
  - Severe hemolysis
- Life cycle
  - Asexual cycle (Schizogony): in humans, formation of merozoites
  - Sexual cycle (Sporogony): in mosquito, formation of sporozoites
  - Definitive host: female *Anopheles* mosquitos (IS: Gametocytes)
  - Intermediate host: Man (IS: Sporozoites)
  - Principal vector: *Anopheles minimus var flavirostris*
  - Secondary: *Anopheles litoralis, Anopheles balabacensis, Anopheles mangyanus, Anopheles maculatus*

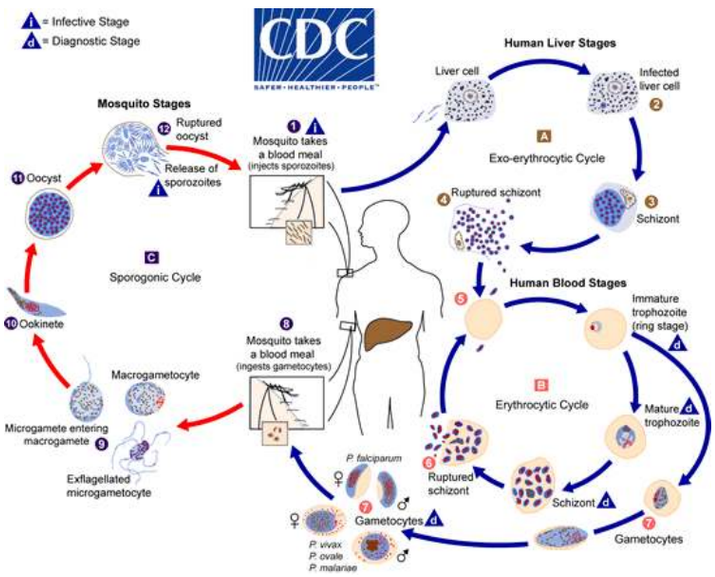

- *Plasmodium vivax and Plasmodium ovale*: reinvade the liver cells, forming hypnozoites
- Merozoites of *P. falciparum* become trophozoites in the RBCs and modify the structural and antigenic properties of these cells
- Mixed infection: *Plasmodium vivax* & *Plasmodium falciparum*
- Treatment
  - Chloroquine: mainstay antimalarial treatment
- Resistant to malaria: G6PD deficiency, Fy (a-b-), Sickle cell disease
- Species
  - *Plasmodium vivax*
    - Most common in the world
  - *Plasmodium falciparum*
    - Most common in the Philippines
  - *Plasmodium malariae*
    - Least pathogenic; Has the longest life cycle
  - *Plasmodium ovale*
    - Least frequent of the malarias
  - *Plasmodium knowlesi*
    - Morphologically similar to *Plasmodium malariae*

	P. vivax	*P. falciparum*	*P. malariae*	*P. ovale*
Asexual phase	48 hours	36-48 hours	72 hours	48 hours
Disease	Benign Tertian	Malignant Tertian	Benign Quartan	Benign Tertian
Pigments	Schauffner's	Maurer's	Ziemann's	James'
Merozoites	10-22	6-20	4-8 (Rosette)	8-12
Gametocytes	Spherical	Banana/ Crescent	Spherical	Large Oval
Infected RBCs	Enlarged	Normal	Normal or Small	Enlarged (Irregular edges)
Late trophozoite	Amoeboid/ irregular	Comma-shaped	Band formation	Round

- Diagnosis
  - Thick and Thin blood smear (Giemsa and Wright)
    - Thick: wash away the RBCs so only parasites remain and stack; used for quantitation or determining the burden of infection
    - Thin: spread; used for species identification
  - Obtain smears every 6-8 hours
  - Histidine-rich protein 2 (HRP-2): produced by *P. falciparum* (MalaQuick); an antigen test
  - Parasite LDH: distinguish between *P. falciparum* and *non-P. falciparum* (OptiMal)

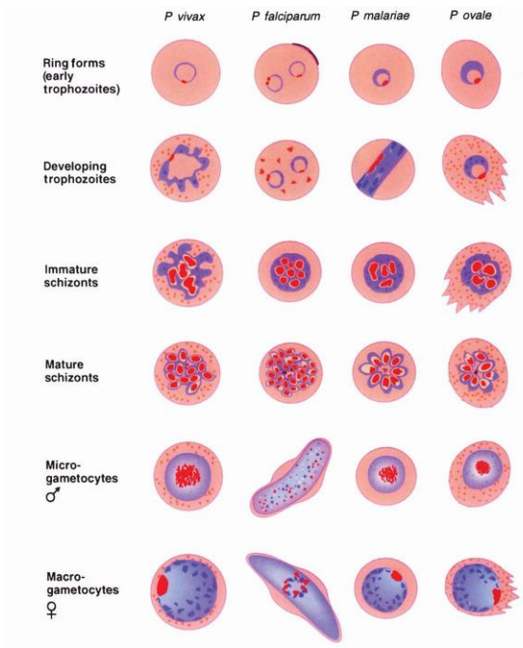

Babesia microti

- Maltese cross formation in RBCs
- Resembles *P. falciparum* rings
- Definitive host: Deers
- Accidental host: Humans
- Mode of transmission: Ixodes tick bite, blood transfusion
- *B. bigemia*: causes "red water fever" in cattle

QUESTION AND ANSWER PORTION

1. What parasite causes Kala-azar?
   a. *T. cruzi*
   b. *T. brucei complex*
   c. *L. donovani*
   d. *L. tropica*
2. This malarial parasite exhibits a 72-hour cycle in its asexual phase
   a. *P. vivax*
   b. *P. falciparum*
   c. *P. ovale*
   d. *P. malariae*
3. Red/pink donut shaped organisms in a blue background when stained with Kinyoun acid fast stain is characteristic of?
   a. *Cytoisospora belli*
   b. *Toxoplasma gondii*
   c. *Sarcocystis hominis*
   d. *Cryptosporidium hominis*
4. What is the vector for the parasite that causes dumdum fever?
   a. *Phlebotomus*
   b. *Glossina*
5. What form of hemoflagellates are ovoidal without flagella?
   a. Leishmanial
   b. Leptomonal
   c. Crithidial
   d. Trypanosomal
6. Which of the following is the culture medium for *L. donovani*?
   a. NNN
   b. Weinman's
   c. BAP
   d. Modified Diamond
7. Infected RBCs of what *Plasmodium* spp. acquire irregular edges?
   a. *P. vivax*
   b. *P. falciparum*
   c. *P. malariae*
   d. *P. ovale*
8. The Sabin-Feldman dye test is a diagnostic test for which of the following protozoans?
   a. *E. histolytica*
   b. *C. hominis*
   c. *T. gondii*
   d. *P. falciparum*
9. Which of the following protozoans were previously identified with cyanobacteria due to their photosynthesis?
   a. *C. cayatenensis*
   b. *C. hominis*
   c. *C. parvum*
   d. *C. belli*
10. What malarial antigen is produced only by *P. falciparum* strains?
   a. HRP II
   b. pLDH
   c. Plasmodium aldolase
   d. Fy6

NEMATODES

INTESTINAL NEMATODES

- Separate sexes
  - Female: larger, pointed tail
  - Male: smaller, curved tail

ACCORDING TO CHEMORECEPTORS

- Aphasmids: lack caudal chemoreceptors (TCT); chemoreceptors are used to detect the nutrients that needs to be ingested by the parasite
  - *T. trichiura*
  - *C. philippinensis*
  - *T. spiralis*
- Phasmids: with caudal chemoreceptors
- Amphids: with cephalic chemoreceptors

ACCORDING TO PROGENY

- Oviparous: lays unembryonated eggs
- Ovoviviparous: lays embryonated eggs
- Viviparous: lays larval stages

ACCORDING TO HABITAT

- Frequency: *E. vermicularis* > *A. lumbricoides* > *T. trichiura* (EAT)

- Small intestine (CASH)
  - *C. philippinensis*
  - *A. lumbricoides*
  - *S. stercoralis*
  - Hookworm
- Large intestine (ET)
  - *E. vermicularis*
  - *T. trichiura*
- Heart and Lung Migration (ASH)
  - *A. lumbricoides*
  - *S. stercoralis*
  - Hookworm

- Unholy three (HAT)
  - Hookworm
  - *A. lumbricoides*
  - *T. trichiura*

Ascaris lumbricoides

- Common name: Giant intestinal roundworm, Pink worm
- Most common intestinal nematode of man (others: *E. vermicularis*), largest
- Habitat: small intestine
- Infective stage: embryonated egg (embryonates at the soil)
- Diagnostic stage: fertilized egg, unfertilized egg (all female worms), adult worm
- Diagnosis
  - DFS
  - Kato Thick
  - Kato-Katz
  - FECT

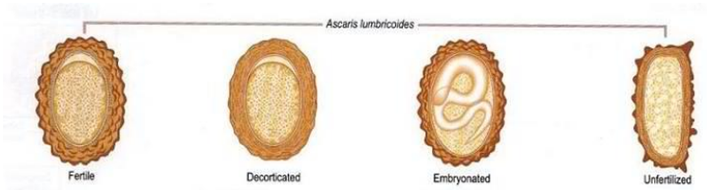

	FERTILIZED	UNFERTILIZED
Appearance	Organized granules, ovoid	Disorganized granules, irregular
Layers	Vitelline Glycogen Mammillary/Albuminous	Glycogen Mammillary
Development	Further developed into larvae	No further development

- Pathogenesis
  - Larval migration
    - Resembles Loefflers syndrome, accumulation of eosinophils in the lungs
  - Intestinal perforation
  - Increased IgE
  - Pneumonitis: larval migration to lung
  - Gangrene due to obstruction (hypoxia and no nutrients)
- Treatment
  - Albendazole
  - Mebendazole
  - Pyrantel pamoate

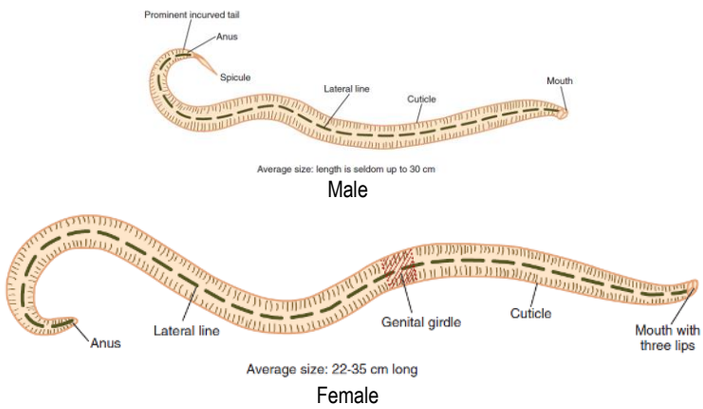

Trichuris trichiura

- Common name: Whipworm
- Habitat: Large intestine
- Infective stage: Embryonated egg
- Diagnostic stage: Unembryonated egg
- Egg
  - Lemon, barrel, football, Japanese-lantern shaped
- Pathogenesis
  - May predispose *E. histolytica* invasion
  - Iron deficiency anemia (Microcytic, hypochromic) due to blood loss
  - Rectal prolapse
- Drug of choice: Albendazole

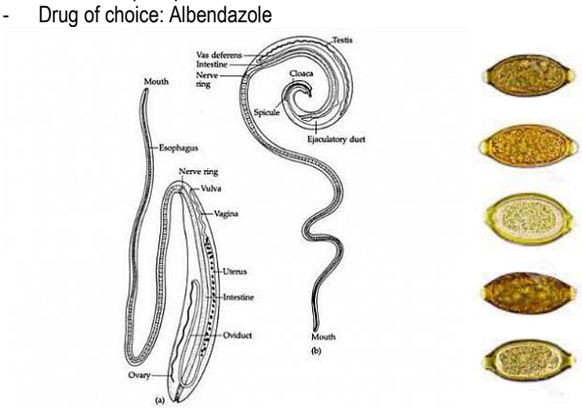

HOOKWORMS

- Common names
  - *N. americanus*: New World Hookworm, American murderer
  - *A. duodenale*: Old World Hookworm, Larger than *N. americanus*
  - *A. caninum*: Dog hookworm
  - *A. braziliense*: Cat hookworm
- Agent of laziness in poor white population and tropical anemia in Puerto Rico
- Blood-sucking nematodes that attaches to the mucosa of the small intestine
- Habitat: small intestine
- Infective stage: Filariform larva
- Diagnostic stage: Eggs, ova, or larva
- Mode of transmission: Skin penetration
- Drug of choice: Albendazole
- Adult worms
  - *N. americanus:* presence of semilunar cutting plates, S-shaped, forms a hook, fan-like bursa copulatrix
  - *A. duodenale*: 2 pairs of ventral teeth, C-shaped

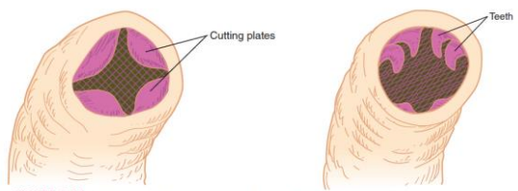

FIGURE 8-14 *Necator americanus*, buccal capsule. FIGURE 8-16 *Ancylostoma duodenale*, buccal capsule.

- Egg
  - Same for all species
  - Ovoidal, thin-shelled, transparent
  - 2-8 germ layers
  - Morula ball appearance

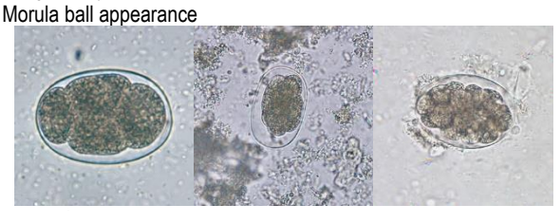

- Pathogenesis
  - Itching (Cooley itch, Ground dew itch, Mazza mora)
  - Microcytic, hypochromic (Iron deficiency Anemia)
  - Hypoalbuminemia, GIT bleeding
  - Pulmonary or Wakanscis disease
  - Cutaneous larva migrans (creeping eruption):
    - *A. caninum*
    - *A. braziliense*
- Diagnosis
  - Harada mori technique

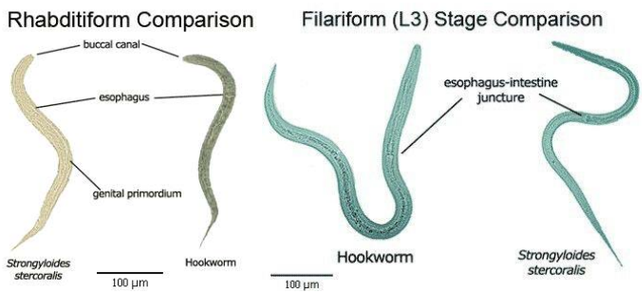

Strongyloides stercoralis

- Causes Cochin-China/Vietnam Diarrhea
- Common name: Threadworm
- Habitat: Small intestine
- Infective stage: Filariform larva
- Diagnostic stage: Rhabditiform larva
- Mode of Transmission: Skin penetration
- Facultative parasite (free-living in the soil)
- Female capable of parthenogenesis (produces larva without a male partner)
- Capable of internal autoinfection
- Clinical manifestations
  - Pneumonitis
  - Diarrhea and malabsorption
  - Secondary bacteremia (*C. freundii* and *E. coli*)
- Diagnosis:
  - Harada mori technique
  - Baermann funnel concentration technique

	HOOKWORM	*Strongyloides stercoralis*
Rhabditiform larva Feeding stage, short and stout	Long buccal cavity Genital primordium: small and inconspicuous	Short buccal cavity Genital primordium: Conspicuous/prominent
Filariform larva Non-feeding stage, long and slender	(+) sheathed Tail: pointed	(-) sheathed Tail: notched

Enterobius vermicularis

- Causative agent of enterobiasis or oxyuriasis
- Common name: Pinworm, seatworm, daycare worm, social worm, inhaled worm
- Habitat: large intestine
- Infective stage: embryonated egg
- Diagnostic stage: embryonated egg
- Capable of external autoinfection (eggs are laid at the perianal region)
- Eggs
  - Elongated, flattened on one side
  - D-shaped
  - Become embryonated in the perianal region after 4-6 hours
- Diagnosis
  - Graham's scotch tape technique for 7 days
- Mother's complex
  - Pruritus ani – main symptom
  - Lack of sleep
  - Extraintestinal enterobiasis

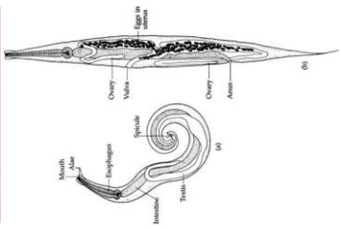

Capillaria philippinensis

- First reported from Northern Luzon in 1963
- Causative agent of Mystery disease/Pudoc's disease
- Common name:
  - Pudoc worm
  - Mystery worm
  - Bagsit worm
  - Peanut-shaped egg
- Habitat: small intestine
- Infective stage: L3 larva or 3rd stage larva
- Diagnostic stage: unembryonated egg
- Mode of transmission: ingestion of undercooked fish
- Natural definitive hosts: fish eating birds
- Accidental hosts: Humans
- Egg
  - Peanut-shaped with striated shells and flattened bipolar ends
  - Must reach water to be ingested by freshwater or brackish water fish
- Pathogenesis
  - Borborygmi: gurgling of the stomach
- Treatment
  - Mebendazole: drug of choice

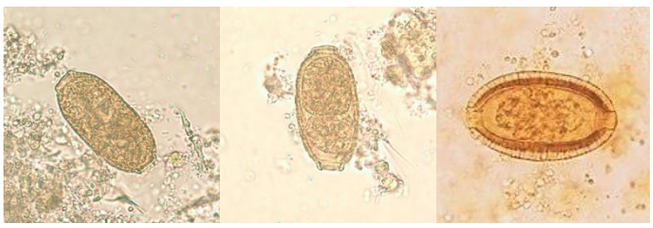

QUESTION AND ANSWER PORTION

1. What is the natural definitive host of *Capillaria philippinensis*?
   a. Freshwater fish
   b. Man
   c. Fish-eating birds
   d. Cats
2. Which of the following is capable of external autoinfection?
   a. *S. stercoralis*
   b. *E. vermicularis*
3. The small intestine is the habitat for the following nematodes except?
   a. *E. vermicularis*
   b. *A. lumbricoides*
   c. Hookworm
   d. *C. philippinensis*
4. The characteristic "morula ball" ovum is exhibited by?
   a. *A. caninum*
   b. *S. stercoralis*
   c. *A. lumbricoides*
   d. *C. philippinensis*
5. What nematode is characterized by a rhabditiform larva with an inconspicuous genital primordium?
   a. Hookworm
   b. *S. stercoralis*
6. The following infections are acquired through skin penetration except:
   a. Oxyuriasis
   b. Hookworm infection
   c. Cochin-China diarrhea
   d. None of the above
7. The following intestinal nematodes can cause complication in the lungs except:
   a. *A. lumbricoides*
   b. *S. stercoralis*
   c. *A. duodenale*
   d. None of the above
8. What is the diagnostic stage for hookworm infections?
   a. Egg
   b. Rhabditiform larva
   c. Filariform larva
   d. 3rd stage larva
9. Gurgling of the stomach is a characteristic symptom of what infection?
   a. Its mode of transmission is skin penetration
   b. Its infective stage is filariform larva
   c. Its diagnostic stage is rhabditiform larva
   d. None of the above
10. Eggs with thickened bipolar plugs are pathognomonic of which parasite?
    a. *A. lumbricoides*
    b. *T. trichiura*
    c. *N. americanus*
    d. *C. philippinensis*

TISSUE NEMATODES

Trichinella spiralis

- Common name: Trichina worm/Muscle worm/Great Imitator
- Viviparous
- Adult worms are found in the: small intestine
- Larvae are found in: muscle fibers
- Man is a dead-end host (both intermediate and definitive host)
- Mode of transmission: ingestion of uncooked pork
- Infective and Diagnostic stage: encysted larva



- Pathogenesis
  - Enteric phase: resembling acute food poisoning
  - Invasion phase: eosinophilia, myalgia, periorbital edema
  - Convalescent phase: encysted larva in muscle, brain damage
- Diagnosis
  - Muscle biopsy: most definitive
  - Immunotests: Bentonite flocculation test, Bachmann intradermal test
  - Xenodiagnosis: using Beck's technique

Parastrongylus cantonensis

- Previously classified under the genus *Angiostrongylus*
- Causative agent of eosinophilic meningoencephalitis
- Common name: Rat-lung or Rodent-lung worm
- Intermediate host: Giant African Snail (*Acanthina fulica*)
- Definitive host: Common rats (*Rattus rattus*)
- Mode of transmission: ingestion of mollusks with 3rd stage larva
- Adult female worm has a characteristic barber's pole pattern of uterine tubules

Dracunculus medinensis

- Longest nematode of man (up to 1 meter)
- Causative agent of Dracontiasis, Dracunculiasis
- Common names: Israeli, Medina, Dragon, Guinea, Fiery Serpent worm
- Intermediate host: cyclops, copepods, water cress
- Definitive host: humans
- Mode of transmission: ingestion of cyclops in contaminated water

Anisakis spp.

- Causative agent of Herring's disease
- 1st IH: marine crustaceans
- 2nd IH: small fishes
- 3rd IH: large fishes
- Definitive host: dolphins, whales
- Mode of transmission: ingestion of raw fishes

Visceral Larva Migrans *(Toxocara spp.)*

- Causes Toxocariasis/VLM
- Common names:
  - *Toxocara canis*: Dog ascarid
  - *Toxocara cati*: Cat ascarid

Cutaneous Larva Migrans *(Ancylostoma spp.)*

	A. braziliense	*A. caninum*	*A. ceylanicum*
Common name	Cat hookworm	Dog hookworm	Golden hamster hookworm
Teeth	2 pairs of large teeth With inconspicuous median teeth	3 pairs of ventral teeth	1 pair of ventral teeth

FILARIAL PARASITES

- Vector-borne nematodes
- Definitive host: humans (IS to humans: 3rd stage larva)
- Intermediate host: Vectors (IS to vectors: Microfilariae)
- Diagnostic stage: Microfilariae
- Pathogenesis
  - Expatriate syndrome: clinical and immunologic hyper-responsiveness to the mature or maturing worms
  - Lymphangiectasia: parasite-induced lymphatic dilatation
  - Fibrosis and cellular hyperplasia: most common chronic manifestation
  - Milky urine (lymphatic fluid)
  - Tropical pulmonary eosinophilia (TPE): occult filariasis
  - Dermatolymphoangioa denitis (DLA): sign of active infection
- Treatment
  - DEC (Diethylcarbamazine): drug of choice
- Diagnosis
  - Knotts concentration technique: for low intensity infections
  - DEC provocative test
  - CFA (circulating filarial antigens)

	HABITAT/ SPECIMEN	VECTOR/ PERIODICITY	MICROFILARIAE/ DISEASE
Wuchereria bancrofti	Lymphatics Blood	*Aedes, Anopheles* Nocturnal (10pm – 2am)	Sheathed, nuclei absent at the tail Bancroftian elephantiasis
Brugia malayi	Lymphatics Blood	*Mansonia* Nocturnal	Sheathed, with 2 nuclei at the tail Malayan elephantiasis
Loa loa	Subcutaneous tissue Blood	*Chrysops* Diurnal	Sheathed, continuous nuclei Calabar swellings/ Fugitive swellings
Onchocerca volvulus	Subcutaneous tissue Skin snips, shavings	*Simulium* (Black fly) Nonperiodic	Unsheathed, nuclei absent at the tail River blindness
Dipetaloma perstans	Body cavities Blood	*Culicoides* Nonperiodic	Unsheathed, nuclei up to the tip of its tail
Monsanella ozzardi	Body cavities Blood	*Culicoides* Nonperiodic	Unsheathed, no nuclei at the tip

Microfilaria	Head end	Tail end	Features*
Wuchereria bancrofti	Sheath Cephalic space (1:1) Coarse nuclei well seprated	No nuclei in the tail tip Pointed tail tip	A: 240–300 µm B: Nocturnal C: Sheathed D: Blood
Brugia malayi	Sheath Cephalic space (2:1) Darkly stained large coarse overlapping nuclei	Four to five nuclei in the tail region Two widely spaced nuclei in tail tip	A: 220 µm B: Nocturnal C: Sheathed D: Blood
Loa loa	Sheath Cephalic space (1:1) Coarse nuclei	Column of nuclei extend into tail tip Blunt tail tip	A: 250–300 µm B: Diurnal C: Sheathed D: Blood
Onchocerca volvulus	Cephalic space (large) Coarse and well separated nuclei	Pointed tail tip with no nuclei	A: 200–360 µm B: Non periodic C: Unsheathed D: Skin, eye
Mansonella perstans	Cephalic space Nuclei overlapping	Blunt tail tip with nuclei	A: 190–200 µm B: Non periodic C: Unsheathed D: Blood
Mansonella streptocerca	Cephalic space Fine and well separated nuclei	Blunt, curved tail tip with nuclei	A: 180–240 µm B: Non periodic C: Unsheathed D: Skin
Mansonella ozzardi	Cephalic space (large) Fine and well separated nuclei	Hooked and pointed tail tip with no nuclei	A: 200–230 µm B: Non periodic C: Unsheathed D: Blood

QUESTION AND ANSWER PORTION

1. This filarial worm is also called as the blinding worm due to it causing river blindness?
   a. *Loa loa*
   b. *Wuchereria bancrofti*
   c. *Brugia malayi*
   d. *Onchocerca volvulus*

2. This CLM exhibits 3 pairs of ventral teeth
   a. *A. braziliense*
   b. *A. caninum*
   c. *A. ceylanicum*
   d. *A. duodenale*

3. What is the diagnostic stage of *Trichinella spiralis*?
   a. Embryonated egg
   b. 3rd stage larva
   c. Rhabditiform larva
   d. Encysted larva

4. What is the vector of *Brugia malayi*?
   a. Aedes
   b. Anopheles
   c. Mansonia
   d. Chrysops

5. What is the vector of the filarial worm that is called the "eye worm"?
   a. *Aedes*
   b. *Anopheles*
   c. *Mansonia*
   d. *Chrysops*

6. This parasite causes Herring's disease
   a. *Anisakis spp.*
   b. *Wuchereria*
   c. *Parastrongylus*
   d. *Dracunculus*

7. Which of the following exhibits a "barber's pole" pattern appearance?
   a. *D. medinensis*
   b. *B. malayi*
   c. *P. cantonensis*
   d. *T. spiralis*

8. After examining a blood smear for malarial parasites, you have found sheathed microfilariae with no nuclei at the tail. This is most likely what species?
   a. *W. bancrofti*
   b. *B. malayi*
   c. *L. loa*
   d. *O. volvulus*

9. What is the most definitive test for detection of Trichinellosis?
   a. Bentonite flocculation test
   b. Xenodiagnosis
   c. Serology
   d. Muscle biopsy

10. What technique is used in the detection of low intensity filarial infections?
    a. Knott's
    b. FECT
    c. Kato-Katz
    d. Bachmann's

CESTODES

- Phylum Platyhelminthes
- Class Cestoda
- Adults are flat and ribbon-like
- One intermediate host only
- Found in intestines of man
- No circulatory system
- No digestive tract
- Nervous system only in scolex
- Hermaphroditic (both male and female reproductive systems are present in each segment)
- Cestode body
  - Scolex (head): anterior attachment organ
  - Neck: region of growth (immature proglottids are near the neck, mature ones are near the tail)
  - Strobila: chain of segments or proglottids
- Intermediate hosts
  - Requires 2 intermediate hosts: *D. latum*
  - Require vertebrate intermediate host: *T. solium* (pig) and *T. saginata* (cattle)
  - Require invertebrate intermediate host: *D. caninum*
  - Does not require an intermediate host: *Hymenolepis nana*

ORDER PSEUDOPHYLLIDEA VS CYCLOPHYLLIDEA

	PSEUDOPHYLLIDEA	CYCLOPHYLLIDEA
	False tapeworm (*D. latum*)	True tapeworms
Scolex	Spoon-shaped with bothria (slit-like sucking grooves) No hooklets	Quadrate with cup-like suckers With or without hooklets
Strobila	Anapolytic (not shed)	Apolytic (sheds segments)
Eggs	Operculated Unembryonated Immature	Nonoperculated Embryonated Mature Hexacanth embryo
Intermediate host	2	1

Diphyllobothrium latum

- Common name: Broad fish tapeworm
- Largest tapeworm of man
- Causes Vitamin B12 deficiency anemia, thrombocytopenia, leukopenia, toxemia
- Mode of transmission: ingestion of infected fish
- Eggs
  - Yellowish brown, moderately thick shell with inconspicuous operculum
  - Opposite the operculum is a knob-like thickening
- Adult worm
  - Scolex is spatulate
  - Has 2 bothria or sucking grooves
  - With a dark rosette uterus

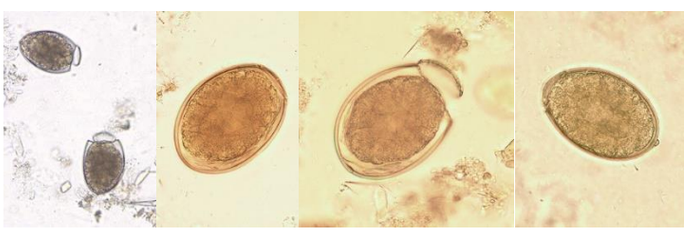

Taenia solium & *Taenia saginata*

- *Taenia saginata*: most common tapeworm of humans
- Eggs are indistinguishable between species

	Taenia solium	*Taenia saginata*
Common name	Pork tapeworm	Beef tapeworm
Disease (Pathogensis)	Taeniasis solium Cysticercosis	Taeniasis saginata
Mode of transmission	Ingestion of infected pork Autoinfection	Ingestion of infected beef
Larva	*Cysticercus cellulosae*	*Cysticercus bovis*
Length	2 – 7 meters	5 – 10 meters
Number of segments	800 – 1000	1000 – 2000
Scolex shape	Globular	Quadrate
Rostellum (organ of attachment)	Present	Absent
Hooklets	Double row of 20-25 hooklets	None



Hymenolepis nana & *Hymenolepis diminuta*

- *Hymenolepis nana*: smallest tapeworm
- *Hymenolepis diminuta:* only Cestode that may not require an IH, autoinfection

	Hymenolepis nana	*Hymenolepis diminuta*
Common name	Dwarf tapeworm	Rat tapeworm
Final host	Humans	Rat (man is only an accidental host)
Eggs	With conspicuous bipolar thickenings and 4-8 polar filaments 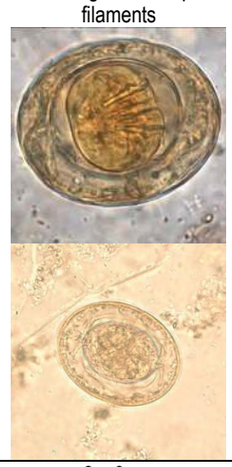	With bipolar thickenings but no polar filaments Fried egg appearance
Length	2 – 8 cm	10 – 60 cm
# of segments	96 – 840	800 – 1300
Scolex shape	Rhomboidal	Club-shaped
Rostellum	Present	Absent
Hooklets	20 – 30 Y-shaped	Absent
Infective stage	Egg	Cysticercoid larva

Dipylidium caninum

- Common name: Dog tapeworm, Double-pored tapeworm, Pregnant tapeworm
- Only tapeworm with 2 genital pores ("Di")
- Pumpkin or vase-shaped proglottids or melon seed
- Intermediate host: *Ctenophalides canis* (dog flea), *Ctenophalides felis* (cat flea), *Pulex irritans* (human flea)

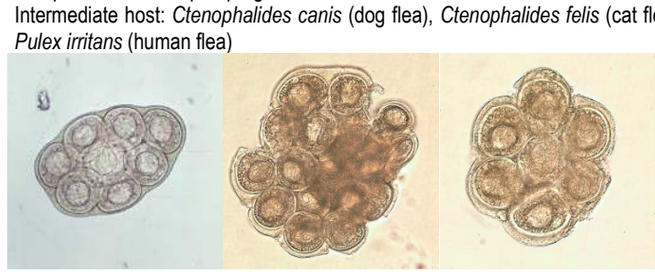

Raillietina garrisoni

- Intermediate host: flour beetles
- Segments: appear like grain of salt or rice grain shaped

Echinococcus granulosus

- Common name: hydatid cyst worm
- Disease: Unilocular echinococcosis, Granular echinococcosis, Hydatid disease
- Smallest, shortest but deadliest tapeworm
- Eggs: resemble *Taenia* eggs
- Body can produce anti-P1 antibodies
- Intradermal test: Casoni test
- Definitive host: dog
- Intermediate host: sheep
- Accidental host: man

Echinococcus multilocularis

- Common name: Fox tapeworm
- Disease: Multilocular echinococcosis, Alveolar echinococcosis
- Ingestion of raw plants contaminated with feces of foxes
- Intermediate host: rodents

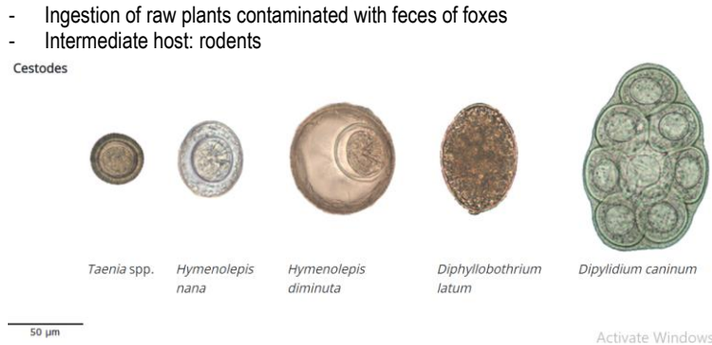

Activate Windows

QUESTION AND ANSWER PORTION

1. This parasite is also called fox tapeworm
   a. *E. granulosus*
   b. *E. multilocularis*
   c. *R. garrisoni*
   d. *D. caninum*
2. This is the only tapeworm with two genital pores in each proglottid
   a. *D. caninum*
   b. *R. garrisoni*
   c. *H. nana*
   d. *T. solium*
3. This cestode can cause cysticercosis
   a. *T. solium*
   b. *T. saginata*
   c. Both
   d. Neither
4. This order consists of the "true tapeworms"
   a. Pseudophyllidea
   b. Cyclophyllidea
5. Which of the following needs 2 intermediate hosts for its development?
   a. Rat tapeworm
   b. Hydatid cyst worm
   c. Broad fish tapeworm
   d. Dwarf tapeworm
6. Which of the following exhibits a rosette nucleus?
   a. Rat tapeworm
   b. Hydatid cyst worm
   c. Broad fish tapeworm
   d. Dwarf tapeworm
7. What do you call the larva of *T. saginata*?
   a. Cysticercus bovis
   b. Cysticercoid bovis
   c. Cysticercus cellulosae
   d. Cysticercoid cellulosae
8. What is the antibody produced against the hydatid cysts of *E. granulosus*?
   a. Anti-P
   b. Anti-P1
   c. Anti-Fy6
   d. Anti-p
9. Direct infection of *H. nana* comes from ingestion of what?
   a. Eggs
   b. Cysticercoid larva
   c. Cysticercus larva
   d. Adult worm
10. This is the region of growth of the cestodes
   a. Scolex
   b. Neck
   c. Strobila

TREMATODES (Flukes)

GENERAL RULES

All except *Schistosoma spp.*	*Schistosoma spp.*
Flat, leaf-like	Elongated and cylindrical
Hermaphrodites	Separate sexes
Operculated	Non-operculated
MOT: Ingestion	MOT: Skin penetration
IS: Metacercariae	IS: Cercariae
2 intermediate hosts	1 intermediate host (snail)

GENERAL CHARACTERISTICS

- Have integuments used for absorption and secretion
- Incomplete digestive system

CERCARIAL STAGES "Maa SCM"

- Miracidium: emerges from the egg, seeks 1st IH
- Sporocyst: develop within the 1st IH
- Cercaria: seeks 2nd IH
- Metacercaria: consumed by man

Mature eggs when laid (SHOC)	Immature eggs when laid (PEFF)
- *Schistosoma*	- *Paragonimus*
- *Heterophyes*	- *Echinostoma*
- *Opisthorchis*	- *Fasciola*
- *Clonorchis*	- *Fasciolopsis*

- 1st IH: snails
- 2nd IH may be fish, crab, plant, snail

2nd INTERMEDIATE HOSTS			
Fish	Plant	Crab	Snail
H. heterophyes *O. felineus* *C. sinensis*	*F. hepatica* *F. gigantica* *F. buski*	*P. westermani*	*E. ilocanum*

HABITAT				
Liver	Lungs	Small intestine	Pancreas	Blood
F. hepatica *F. gigantica* *C. sinensis* *O. felineus* *O. viverrini*	*P. westermani*	*F. buski* *E. ilocanum* *H. heterophyes*	*E. pancreaticum*	*S. japonicum* *S. mansoni* *S. haematobium*

Figure 5: Trematode Eggs Found in Stool Specimens of Humans

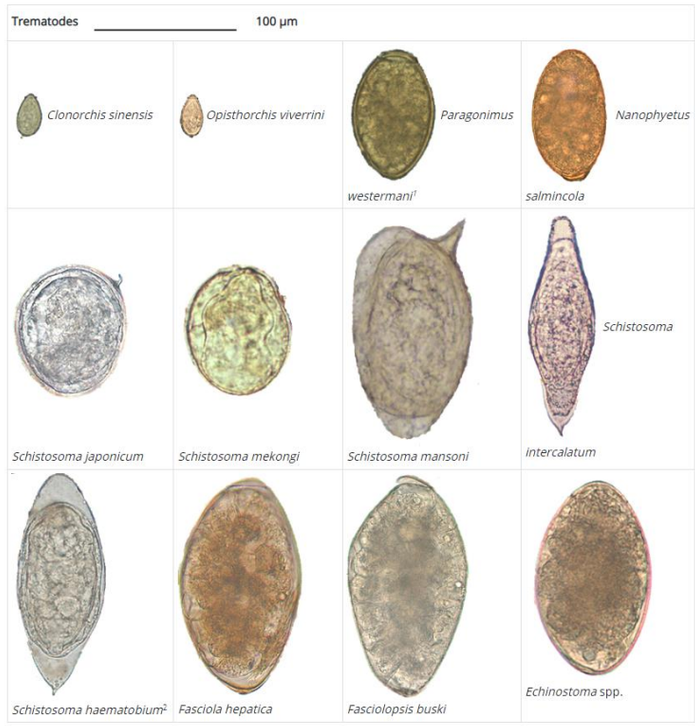

1. Usually found in respiratory specimens.
2. Usually passed in urine.

Trematode Eggs Found in Stool Specimens of Man

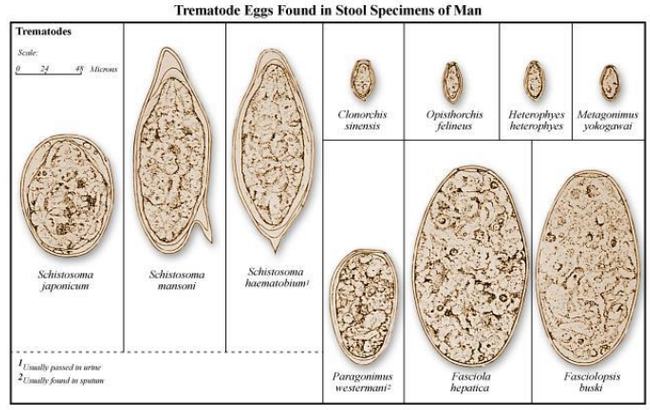

(Adapted from Melvin, Brook, and Sadun, 1959)

Fasciola hepatica & *Fasciolopsis buski*

	Fasciola hepatica	*Fasciolopsis buski*
Common name	Temperate or Sheep Liver Fluke	Giant intestinal fluke
Habitat	Liver, bile ducts	Small intestine
Cephalic cone	Prominent	None
Type of intestine	Branched/Dendritic	Simple/Wavy
Ova	Hen egg shaped ellipsoidal and rounded at both ends	
Pathogenesis	Obstruction of bile ducts Halzuon-Pharyngeal Fascioliasis	Intestinal obstruction Damage and blood loss Toxic due to metabolites
Reservoir host	Sheep, cattle, rabbit	Pigs

Fasciola gigantica

- Common name: Giant liver fluke, Tropical liver fluke
- 1st IH: Snail
- 2nd IH: Aquatic vegetation
- Eggs resemble *F. hepatica* and *F. buski*

Clonorchis sinensis & *Opisthorchis felineus*

- May cause: liver carcinoma
- 1st IH: Snails
- 2nd IH: Fishes

Siberia Liver Fluke

	Clonorchis sinensis	*Opisthorchis felineus*
Common name	Oriental/Chinese Liver Fluke	Cat Liver Fluke
Morphology	Elongated, Gray	Lancet-shaped, Reddish yellow
Suckers	Oral > Ventral Larger	Ventral > Oral
Ova	Smallest Old-fashioned electric light bulb	Lesser prominent operculum or shoulder
Pathogenesis	Gallbladder carcinoma, Cholangiocarcinoma	Liver cirrhosis

Echinostoma ilocanum
- Common name: Garrison's fluke
- 1st and 2nd intermediate host: Snail
- Habitat: Small intestine

Heterophyes heterophyes
- With a 3rd sucker (called genital sucker or gonotyl)
- Smallest but deadliest fluke of man
- 1st IH: snails
- 2nd IH: fishes
- Adult shape: pyriform
- May present with peptic ulcer disease (PUD)

Eurythema pancreaticum
- Definitive hosts: sheeps, goats, pigs
- 1st IH: snails
- 2nd IH: grasshopper, locusts, ants
- May cause pancreatic duct enlargement

Schistosoma spp.
- Most romantic parasite of man
- Causes Schistosomiasis
- Diagnosis
  - Demonstration of eggs
  - Faust and Meleney's egg hatching technique
  - COP (Circumoval Precipitin Test)

	S. japonicum	*S. mansoni*	*S. haematobium*
Common name	Oriental blood fluke	Manson's blood fluke	Vesicle blood fluke Vesical
Habitat	Superior mesenteric veins of the small intestine	Inferior mesenteric veins of the colon and rectum	Portal vein of the urinary bladder (24 hour urine specimen)
Ova	Small lateral knob	Lateral spine	Terminal spine
Disease	Swimmer's itch Katayama fever	Cercarial dermatitis	Urinary Schistosomiasis Terminal hematuria
Intermediate host	*Oncomelania hupensis quadrasi*	*Biomphalaria*	*Bulimus, Physopsis, Biomphalaria*

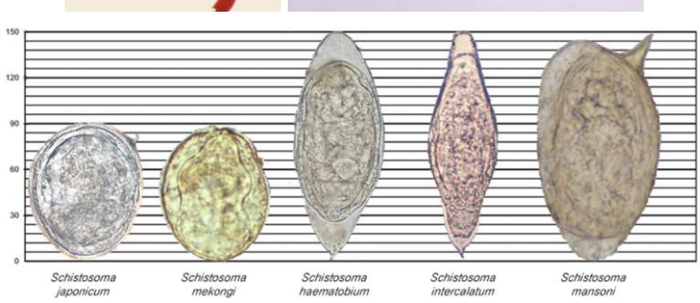

Paragonimus westermani
- Common name: Oriental Lung Fluke
- Causes endemic hemoptysis
- Disease mistaken as PTB
- Adult resembles coffee bean
- Egg: with thickened abopercular end
- 1st IH: Snails
- 2nd IH: Crabs (*Sundathelphusa philippina*)
- Specimen used: sputum, stool

Fasciola hepatica — Sheep Liver Fluke
Fasciolopsis buski — Giant intestinal fluke
Fasciola gigantica — Giant liver fluke
Clonorchis sinensis — Oriental/Chinese liver fluke
Opisthorchis felineus — Cat/Siberia liver fluke
Opisthorchis viverrini — Southeast Asian liver fluke
Paragonimus westermani — Oriental Lung Fluke
Echinostoma ilocanum — Garrison's fluke
Heterophyes heterophyes — Von Siebold's fluke
S. japonicum — Oriental blood fluke
S. mansoni — Manson's blood fluke
S. haematobium — Vesical blood fluke

QUESTION AND ANSWER PORTION

1. What is the 2nd intermediate host of *Paragonimus westermani*?
   a. Fish
   b. Plants
   c. Crabs
   d. Snails
2. Which of the following requires only 1 intermediate host?
   a. *S. japonicum*
   b. *E. pancreaticum*
   c. *F. gigantica*
   d. *F. buski*
3. This trematode has a characteristic "hen's egg" shaped ovum
   a. *S. mansoni*
   b. *S. japonicum*
   c. *F. hepatica*
   d. *O. felineus*
4. Which of the following has an ovum with a small lateral knob?
   a. *S. mansoni*
   b. *S. japonicum*
   c. *F. hepatica*
   d. *O. felineus*
5. This trematode is also known as Garrison's fluke?
   a. *H. heterophyes*
   b. *E. ilocanum*
   c. *D. latum*
   d. *C. sinensis*
6. What is the disease commonly mistaken as PTB?
   a. Paragonimiasis
   b. Schistosomiasis
   c. Both
   d. None of the above
7. What is the specimen used in detecting *S. haematobium?*
   a. Feces
   b. Sputum
   c. 24-hour urine
   d. Bronchoalveolar lavage
8. This is also called grasshopper fluke
   a. *H. heterophyes*
   b. *E. pancreaticum*
   c. *D. latum*
   d. *C. sinensis*
9. The adult fluke of this species resembles a coffee bean
   a. *P. westermani*
   b. *E. ilocanum*
10. All parasitic trematodes are hermaphroditic except what genus?
   a. *Fasciola*
   b. *Fasciolopsis*
   c. *Opisthorchis*
   d. *Schistosoma*

ARTHROPODS

Copepods (Cyclops)	Intermediate host of *Diphyllobothrium latum*
Pthirus pubis	Crab louse Agent of "crabs"
Periplaneta americana	American cockroach May spread hepatitis, poliovirus, *E. histolytica,* and nematodes
Aedes aegypti	Tiger mosquito Vector for urban dengue Vector for *Wuchereria bancrofti*
Culex	Vector for Japanese encephalitis
Anopheles flavirostris	Primary vector of malaria
Musca domestica	Common housefly
Sarcophaga	"Chess-board" appearance Common flesh flies
Phaenicia	Bronze-bottle fly Common green bottle fly

DIAGNOSTIC PARASITOLOGY
- A parasitology laboratory should be able to:
  - Confirm a clinical impression that the condition has a parasitic nature
  - Rule out differential diagnosis
  - Aid a clinician for the proper medication
  - Help in monitoring the effect of a treatment regimen
- Rules:
  - Never freeze stool samples (can be refrigerated)
  - Never keep stool samples in incubators
  - Stool samples should be read within 30 minutes to 1 hour
  - Thumb sized stool: formed or 5-6 tablespoons of water stool

STOOL PRESERVATIVES

1. FORMALIN
- All-purpose fixative
- 5%: for cysts
- 10%: for helminth eggs and larvae
- Used in FECT

2. SCHAUDDIN'S SOLUTION
- Contains mercuric chloride, which is toxic to humans

3. POLYVINYL ALCOHOL (PVA)
- Plastic resin that serves to adhere a stool sample to a slide
- Normally incorporated to Schaudinn's

4. MERTHIOLATE-IODINE-FORMALIN (MIF)
- Merthiolate/Thimerosal and Iodine: staining components
- Formalin: preservative
- Useful for protozoans, helminth eggs, and larvae

5. SODIUM ACETATE-ACETIC ACID FORMALIN (SAF)
- Advantage: does not contain Mercuric chloride
- Disadvantage: not as sharp after staining than PVA or Schaudinn's

EXAMINATION OF STOOL

DIRECT FECAL SMEAR
- 2mg of stool + 0.85% NSS
- Primarily useful in detection of motile protozoan trophozoites
- Lugol's iodine or D'Antoni: used to stain nuclei of cysts

KATO THICK SMEAR
- 50 to 60 mg of stool
- Covered with cut cellophane paper soaked in a mixture of glycerine and malachite green
- Glycerine: clearing solution
- Malachite green: stain

CONCENTRATION TECHNIQUES
- **SEDIMENTATION PROCEDURES**
  - ***Acid Ether Concentration Technique***
    - Sample: preserved stool
    - Main reagents:
      - 40% HCl- dissolve albuminous materials
      - Ether dissolve neutral fats
    - Method for cat and dog stool examination
  - ***Formalin-Ether/Ethyl Acetate Concentration Technique (FECT)***
    - 10% formalin (fixative)+ ether (dissolves neutral fats in stool)
    - Ethyl acetate: more efficient for cestode and Giardia but not as efficient in the extraction of fat
    - *H. nana* eggs may be missed
    - Centrifugation: 500xg for 10 minutes (4 layers)

- **FLOTATION PROCEDURES**
  - ***Zinc Sulfate Flotation***
    - Reagents: 33% Zinc sulfate
    - Ideal SG for fresh stools:
    - Ideal SG for formalinized stools:
    - Centrifugation: 500xg for 2 minutes (2 layers)
  - ***Brine Flotation***
    - Reagent: saturated table salt
    - No need for centrifugation; helminth eggs rise to the surface of the solution
    - Not useful for operculated eggs (*Clonorchis, Opisthorchis*)
  - ***Sheathers Sugar Flotation***
    - Reagent: Boiled sugar solution preserved with phenol (1.25-1.27 SG)
    - Best for the recovery of Coccidian oocysts (*Cryptosporidium, Cyclospora, Cytoisospora*)

STOOL CULTURE METHODS

1. COPRO CULTURE
- Positive stools are mixed with moistened stool or granulated charcoal
- Larvae are harvested using Baermann procedure

2. HARADA-MORI
- Filariform larvae move downward
- *Strongyloides* larvae move upwards

EGG COUNTING PROCEDURES

1. KATO-KATZ METHOD
- Cellophane covered thick smear
- Measured amount of stool has been sieved through a wire mesh
- Useful for assessing the intensity of infection with *Schistosoma* and *Ascaris*, *Trichuris*, and Hookworm
- For the identification of Schistosoma ova, 1% eosin solution can be layered over the cellophane paper

2. STOLL EGG COUNT
- Reagent: 0.1N NaOH acts as diluent and saponifies fat

EXAMINATION OF PERIANAL SWAB
- Used to recover, *E. vermicularis* and *Taenia* eggs
- Cellulose tape or scotch tape method

EXAMINATION OF BLOOD

1. WET/FRESH PREPARATION
- Used to detect microfilariae and trypomastigotes
- Species identification is not possible

2. STAINED SMEARS
- Thick films: 2 to 3 small drops of blood, dehemoglobinized before staining
- Thin films: thick on one end, feathery on other end, fixed with methanol before staining

3. BUFFY COAT FILMS
- *Trypanosoma* and *Leishmania* are concentrated at buffy coat portion

4. QUANTITATIVE BUFFY COAT (QBC)
- Useful for detection of microfilariae, malarial parasites, trypanosomes and *Babesia*
- Acridine orange stain causes fluorescence of DNA of parasites

5. KNOTT'S CONCENTRATION
- 1 mL blood + 10 ml of 2% formalin
- For low microfilaremia

QUESTION AND ANSWER PORTION

1. Duodenal Aspirates or "entero test" is useful for the detection of which of the following parasites?
   a. Giardia duodenalis
   b. Strongyloides stercoralis
   c. Both
   d. None
2. Examination of rectal biopsy material can reveal presence of which of the following?
   a. S. japonicum
   b. S. haematobium
   c. None of the above
3. Liver aspirates can be useful in detecting which of these infections?
   a. Hydatid Cyst disease
   b. Trichomoniasis
   c. Giardiasis
   d. None of the above
4. What is the SG of the zinc sulfate flotation test when using fresh stools?
   a. 1.10
   b. 1.18
   c. 1.16
   d. 1.20
5. What component of the Acid Ether Concentration technique dissolves albuminous material?
   a. 40% HCl
   b. Ether
6. How many layers will there be after the centrifugation of FECT samples?
   a. 2
   b. 4
7. Perianal samples are useful for the detection of?
   a. Enterobius
   b. Taenia
   c. Both
   d. Neither
8. You want to detect coccidian oocysts in the stool sample. What technique is best suited to do so?
   a. Brine Flotation
   b. Zinc Sulfate
   c. Sheathers Sugar Flotation
9. What is the reagent used in Stoll Egg Counting?
   a. NaOH
   b. Eosin
   c. Brine
   d. Phenol
10. You performed a Harada Mori procedure on a stool sample. Larvae then moved upwards. The larvae are most likely what species?
    a. A. duodenale
    b. A. ceylanicum
    c. N. americanus
    d. S. stercoralis